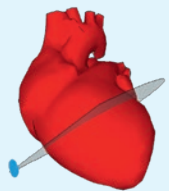
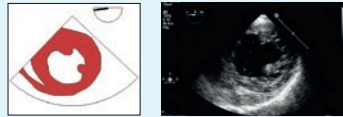


Transösophageale Echokardiografie

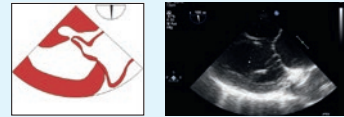
1. TRANSGASTRAL (TG)



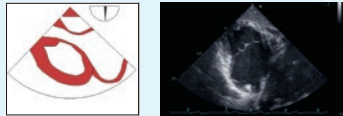
0° TG mid SAX



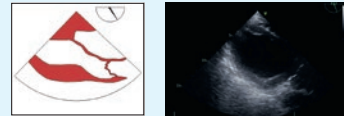
90° TG 2CV



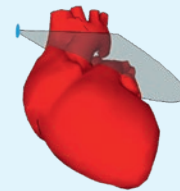
90° TG RVIT




120° TG LAX



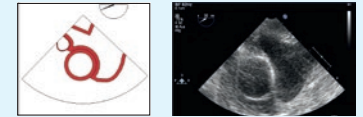
4. OBERER ÖSOPHAGUS (UE)



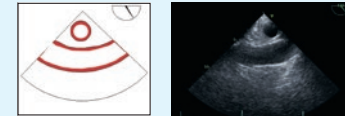
0° UE Ao. arch LAX



20° UE SAX



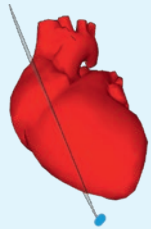
90° UE Ao. arch LAX



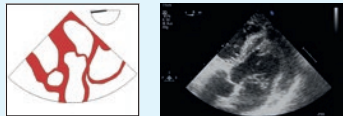
90° UE RVOT



2. TIEF TRANSGASTRAL (deep TG)



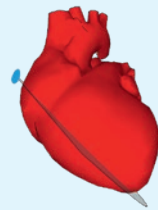
0° deep TG LAX



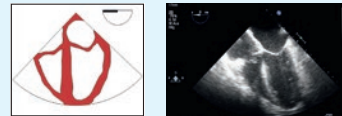
0° deep TG RVOT



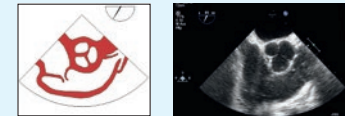3. MITTÖSOPHAGEAL (ME)



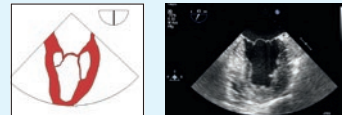
0° ME 4CV



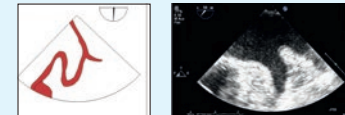
45° ME AV SAX



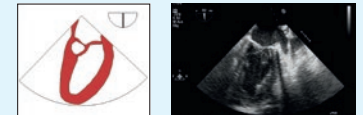
60° ME mitral commissural



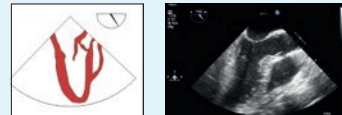
90° ME LAA



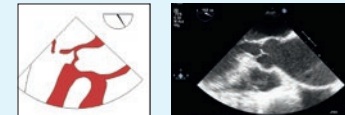90° ME 2CV



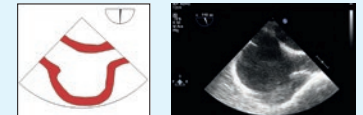120° ME LAX



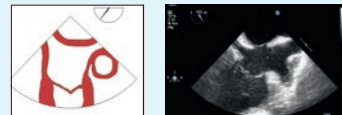120° ME AV LAX



90° ME bicaval



60° ME bicaval TV



0° ME Ao. desc. SAX



90° ME Ao. desc. LAX

